

A prospective study of Autologous Growth Factors (AGF) in lumbar interbody fusion

Louis G. Jenis, MD*, Robert J. Banco, MD, Brian Kwon, MD

Boston Spine Group, New England Baptist Hospital, 125 Parker Hill Ave., Boston, MA 02120, USA

Received 31 March 2005; accepted 25 August 2005

Abstract

BACKGROUND: Numerous preclinical and clinical studies have reported on the use of platelet concentrates to promote tissue healing. The results in spinal fusion applications are limited and controversial.

PURPOSE: The purpose of the current prospective clinical cohort study is to assess the effect of Autologous Growth Factors (AGF) on lumbar interbody fusion with specific attention paid to determination of clinical and radiographic outcomes.

STUDY DESIGN/SETTING: Prospective clinical study

PATIENT SAMPLE: Candidates for anterior-posterior lumbar fusion with diagnosis of degenerative disc disease and/or up to grade I spondylolytic spondylolisthesis based on positive provocative discography.

OUTCOME MEASURES: Clinical (visual analogue pain scale/functional outcome assessment) and radiographic outcomes (fusion on computed tomography at 6 months and plain radiographs at 12 and 24 months).

METHODS: Thirty-seven patients were assigned to standard anterior-posterior interbody fusion L2–S1 (single or two-level) using iliac crest bone graft (autograft group: 22 patients with 32 levels operated) or allograft combined with autogenous growth factors (AGF group: 15 patients with 25 levels operated). Radiographic outcomes were collected at 6 months postsurgery with computed tomography and at 12 and 24 months with plain radiographs. Pre- and postoperative clinical outcome measures included visual analog scores (VAS) for back and leg pain (0–10), SF-36 scores, and Oswestry disability determination. Average clinical and radiographic follow-up for the autograft group was 24.3±5.6 months (12–36 months) and AGF was 25.7±7.5 (6–40 months).

RESULTS: Fusion incorporation at each end plate was determined at 56% in both autograft and AGF (p=NS) patients based on computed tomography at 6 months with minimal subsidence noted and no direct correlation between the incidence or degree of cage subsidence and bone graft technique. The 12- and 24-month radiographic results confirmed an 85% arthrodesis rate for the autograft patients, whereas the AGF patients had an 89% fusion rate (p=NS). Clinical outcomes were similar for both groups and no significant differences were noted for pain or functional outcome improvements.

CONCLUSIONS: AGF combined with an allograft carrier is equivalent in radiographic and clinical outcomes to autograft in one- or two-level lumbar interbody fusion with supplemental posterior fixation and, thus, eliminates any morbidity from iliac crest bone graft harvesting. AGF combined with an appropriate carrier is a reasonable alternative to autograft and expensive bone induction technologies. Further research is still required to examine the optimum carriers, preparation and formulation, and platelet concentrations for this technology. © 2006 Elsevier Inc. All rights reserved.

Keywords:

Platelet concentrate; AGF; Lumbar interbody fusion; Outcomes

FDA device/drug status: approved for this indication (Autologous Growth Factors).

Nothing of value received from a commercial entity related to this manuscript.

* Corresponding author. Boston Spine Group, 125 Parker Hill Ave., Boston, MA 02120. Tel.: (617) 754-6363; fax: (617) 754-5593.

E-mail address: ljenis@caregroup.harvard.edu (L.G. Jenis)

Introduction

A basic paradigm of healing after injury exists universally among all tissues. Platelets are a key component of the initial cellular response in tissue repair by migrating to the injury site and releasing a variety of growth factors.

This early platelet-mediated activity induces formation of a structural, organized fibrin clot as well as chemotaxis of white blood cells and various noncommitted progenitor stem cells. Platelet degranulation and release of platelet-derived growth factor, transforming growth factor-beta, and vascular endothelial growth factor are among the known signaling substances to be important in fracture healing [1–4]. Tissue-specific differentiation and repair is then directed by other factors including bone morphogenic protein and transforming growth factor-beta.

This platelet-mediated wound healing response provides theoretical rationale for use in clinical practice [5–8]. Because platelets are a source of multiple growth factors, increasing their number and concentration to an injury site may lead to a synergistic effect on tissue repair. A platelet concentrate has several potential benefits in addition to enhancement of a tissue healing response, such as provision of a fibrin-based clot serving as a scaffold for cellular attachment and improvement of handling characteristics of a tissue-engineered graft.

Feasibility studies have been performed on the development of platelet concentrates for clinical use by means of centrifugation techniques [9–12]. Platelets can be sequestered from whole blood, leaving red blood cells and plasma (platelet-poor plasma). More advanced ultrafiltration methods result in *superconcentrated* plasma of up to 8–10 times that of whole blood. This proprietary platelet concentration system has been termed Autologous Growth Factors (AGF) (Interpore Cross, Irvine, CA).

Numerous preclinical and clinical studies have reported on the use of platelet concentrates to promote tissue healing. The results in spinal fusion applications are limited and controversial. Studies have described both beneficial effects of fusion incorporation as well as inhibitory reaction to platelet addition to autologous graft [13–17].

The purpose of the current study is to assess the effect of AGF compared with autograft iliac crest bone on lumbar interbody fusion, with specific consideration paid to determination of clinical and radiographic outcomes.

Materials and methods

Study group

Institutional review board approval was obtained for admission of human subjects into this study before the commencement of patient enrollment and informed consent. Two fellowship-trained orthopedic spine surgeons contributed patients deemed to be candidates for single or two-level anterior-posterior lumbar fusion to the study in a period from July 2000 through November 2002 and personally obtained verbal and written consent from each patient. Preoperative evaluation of the pain generator included the use of magnetic resonance imaging, radiographs, and provocative discography. Patients were assigned to

standard anterior-posterior interbody fusion using iliac crest bone graft (autograft group; n=22) or allograft combined with autogenous growth factors (AGF group; n=15) based on availability of cell saver technology on the day of surgery.

Inclusion criteria included: at least 12-month history of low back pain with or without associated radiculopathy clinically determined to be localized to one or two disc spaces from L3 to S1 by radiographic evaluation including provocative discography; diagnosis limited to degenerative disc disease or spondylolisthesis (spondylolytic or degenerative) with less than or equal to 25% anterior vertebral body translation; exhaustion of a conservative, multidisciplinary treatment program including physical therapy, injection therapy, and oral pain medication when indicated lasting at least 6 months; age range from 20 to 60; and patient-derived visual analog score for back pain at least 7 on a scale of 0–10. Exclusion criteria included history of prior abdominal surgery requiring retroperitoneal exposure; previous spinal infection; greater than 25% spondylolisthesis; metabolic bone disease; and inability to comply with clinical follow-up regimen.

Operative procedure

An anterior retroperitoneal lumbar approach was initially performed in all patients. All interbody disc preparation was similar, with aggressive radical discectomy with preservation of the peripheral cortical end plates. Central end plate perforations were made with curettes or burr. Unilateral iliac crest graft was harvested via a 4–5-cm incision overlying the pelvis, with preservation of the inner and outer table of the ilium. Morselized graft was harvested and added to an “upright” titanium mesh cage (Harms Cage, DePuy Spine, Raynham, MA or Pyramesh, Medtronic, Memphis, TN) and inserted into the distracted disc space in the control group. Study patients had cancellous allograft “chips” combined with AGF (technique below) added to the cage and inserted into the disc space. Bone graft volume was standardized for each group and was measured at 15–20 cc/disc space. Device positioning was confirmed with intraoperative imaging studies. Each patient then underwent same-day posterior lumbar exposure and insertion of transpedicular instrumentation. Additional iliac crest graft was harvested from the posterior superior iliac spine with preservation of the inner and outer tables of the ilium in all control and study patients and added to the bilateral intertransverse process area to complete the 360-degree fusion procedure.

Standard postoperative management was employed for all patients, including initial pain control via intravenous narcotics, early mobilization, home exercises, and avoidance of nonsteroidal anti-inflammatory agents. All patients were educated and encouraged on nicotine cessation. Postoperative external bracing was not consistently prescribed or worn by patients.

Radiographic outcomes

Radiographic assessment was performed by one of us not involved in the surgical or postoperative care of the patients and was masked to the interbody graft composition. At 6 months after surgery, each patient underwent computed tomography with reconstructed 1.5-mm images in the sagittal and coronal planes (GE, Milwaukee, WI). Solid interbody arthrodesis required obvious complete incorporation into both the superior and inferior end plates at each disc level. Radiographic follow-up at 12 months, 24 months, and longer evaluation included standing lateral flexion and extension dynamic studies. Fusion was defined by the lack of observable motion between the spinous processes or the presence of a sentinel sign of bone formation (anterior to the cage along the vertebral body margins). Specific attention was drawn to the presence of cage subsidence and posterior instrumentation loosening.

Clinical outcomes measures

Outcomes analysis included preoperative demographics assessment, including work status, medication, and nicotine usage. Self-assessed visual analog scores (0 least to 10 most) were recorded for preoperative back in addition to the 36-Item Short Form Health Survey (SF-36) [18] and the Oswestry disability index [19].

Autologous Growth Factor preparation

Induction of general anesthesia was followed by sequestration of one unit of whole blood (approximately 450 cc) from the AGF patients. Centrifugation resulted in three components including red blood cells and platelet-poor plasma, and a buffy coat containing cellular elements including platelets and white blood cells. The buffy coat was placed into an ultraconcentrator and the eventual formation of a platelet-rich solution. The AGF was then added to thrombin and mixed with crushed cancellous allograft chips. The red cells and platelet-poor plasma were reinfused into the patient.

Statistical analysis

Clinical and functional outcome data were analyzed using a paired *t* test for comparisons using the SMS program. A *p* value of <.05 was accepted as statistically significant.

Results

Thirty-seven patients were entered into the study. Table 1 defines the demographic characteristics of the AGF (study) and autograft (control) groups. Average clinical and radiographic follow-up for the autograft group was 24.3±5.6 months (12–36 months), and for the AGF group was 25.7±7.5 (6–40 months). One AGF patient was lost to follow-up at 6 months and only had early clinical and

Table 1
Demographic characteristics of study and control groups

| | AGF (n=15) | Autograft (n=22) | p Value |
|-------------------------------|---------------|------------------|---------|
| Age | 40.3±7.5 | 41.4±8.0 | NS |
| Range | (30–52) | (28–58) | |
| Gender | 10 M 5 F | 14 M 8 F | |
| Nicotine use | 40% | 23% | NS |
| Previous surgery (discectomy) | 0 | 1 | |
| Workers' Compensation | 60% | 68% | NS |
| Estimated blood loss | 793±349cc | 766±496cc | NS |
| Surgical time (min) | 315±4.6 | 293±59 | NS |
| Preop black VAS | 7.5±1.1 (4–8) | 7.7±1.7 (4–10) | NS |

AGF=Autologous Growth Factors; VAS=visual analog score.

computed tomographic data included in the study. Fusion levels for the autograft group included 32 total levels operated upon: 12 single-level (L5–S1, 6 and L4–L5, 6) and 10 two-level fusion (L4–S1, 8, L3–L5, 1, and L2–L4, 1). Twenty-five fusion levels in the AGF group included 5 single-level (L5–S1, 4 and L4–L5, 1) and 10 two-level fusion (L4–S1, 9 and L3–L5, 1).

Radiographic analysis at 6 months included computed tomography with sagittal and coronal reconstructions. Fusion incorporation at each end plate was determined at 56% in both the autograft (18/32 levels) and AGF (15/22 levels) groups (*p*=NS) (Table 2, Fig. 1). Minimal subsidence was observed on a variable basis, and no direct correlation could be made between the incidence or degree of cage subsidence and bone graft technique. Plain radiographs were obtained at 12 and 24 months. The 24-month data are reported in Table 2 and Figure 2. The autograft group of patients were determined to have an 85% arthrodesis rate based on the presence of a sentinel sign or lack of motion on dynamic testing, whereas the AGF patients had an 89% fusion rate (*p*=NS).

Clinical results of back pain are shown in Table 3. Each group experienced an improvement of their pain symptoms from preoperative compared with long-term follow-up. No significant differences were noted between the groups in pain relief or in functional outcome based on Oswestry scores and SF-36 analysis (Table 4). Pain reduction ratios were similar between AGF patients (0.38±0.4) and autograft patients (0.36±0.35).

No significant adverse events were related to the whole blood sequestration or red cell reinfusion techniques in the AGF patients. No new onset radiculopathy or postoperative wound infections were found. One AGF patient experienced an injury to the left common iliac vein during the

Table 2
Radiographic analysis

| | AGF | Autograft |
|-------------------------|-----|---------------------|
| CT scan (6 months) | 56% | 56% (<i>p</i> =NS) |
| Radiographs (24 months) | 89% | 85% (<i>p</i> =NS) |

AGF=Autologous Growth Factors; CT=computed tomography.

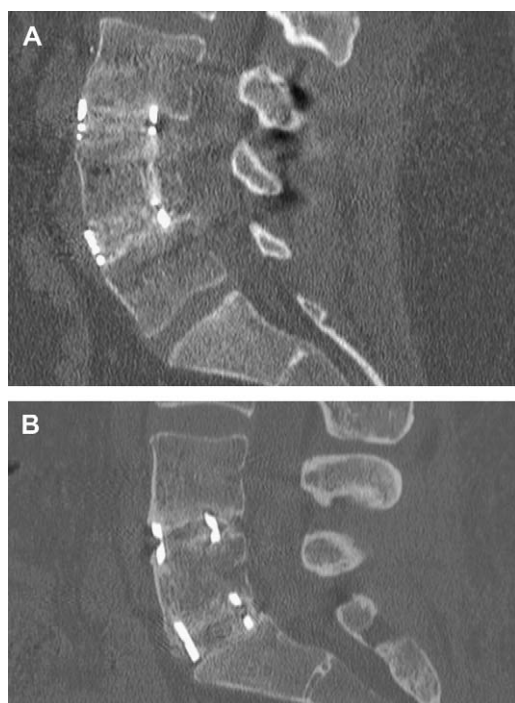

Fig. 1. Computed tomographic mid-sagittal reconstructed images of patient at 6 months after anterior/posterior fusion at L3–L4 and L4–L5 treated with titanium mesh cage and Autologous Growth Factors (AGF)–allograft bone (A); autograft (B) at L4–L5 and L5–S1 in the interbody space.

retroperitoneal approach that required repair, completion of the anterior procedure, and staging of the posterior surgery 5 days later. One symptomatic pseudarthrosis was noted in the AGF group, requiring revision posterior surgery.

Discussion

To our knowledge, this is the first prospective clinical cohort study to address the role of platelet concentrates in anterior interbody lumbar fusion. The purpose of this study was to assess the effect of AGF on radiographic and clinical outcomes and to determine if the proposed advantages of a concentration of platelets could promote successful arthrodesis while limiting the use of autogenous bone graft in an anterior lumbar interbody fusion model. It is important to note that we did not avoid harvesting iliac crest autogenous graft in the posterior spinal procedure. This study focuses on the interbody fusion with additional posterior fixation and autogenous graft in the intertransverse area.

The morbidity of autogenous graft harvest is controversial although there are several reports on the incidence of pain following these procedures. It is estimated that there are nearly 800,000 bone grafting procedures performed annually in the US and that roughly 55% are specifically for spinal fusion. Nearly two-thirds of these procedures involve harvesting of the iliac crest for bone graft procurement. Autograft has significant advantages and is considered the

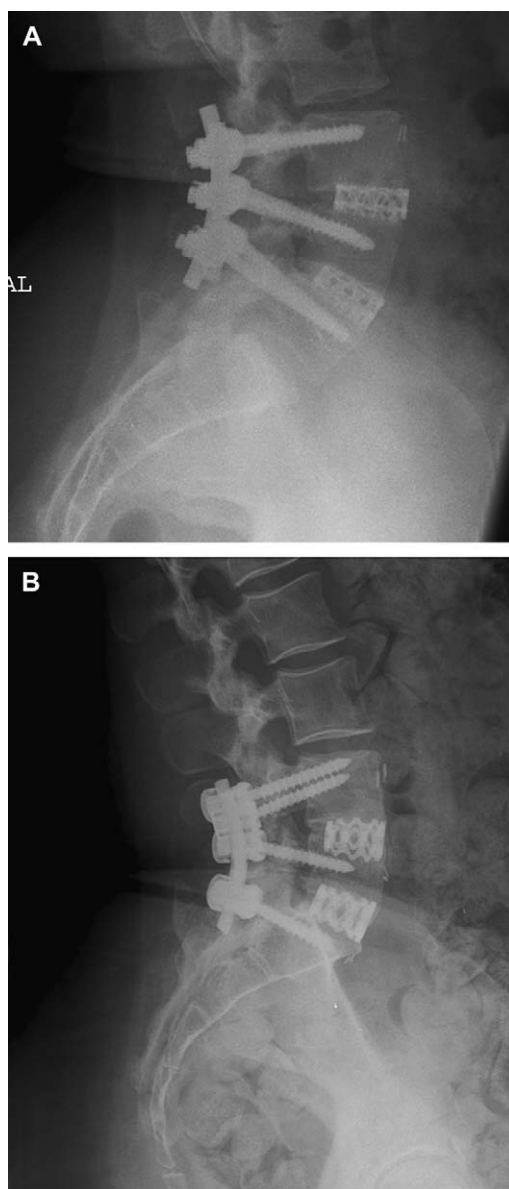


Fig. 2. Plain radiographs at 1-year follow-up for autologous growth factors (AGF)–allograft fusion (A) and autograft (B) for the same patients.

“gold standard” for fusion procedures because of the inherent properties of osteoconduction, osteoinduction, and provision of a cellular component for bone healing. However, graft site complications and morbidity are not uncommon, including wound infection, hematoma, iliac crest fracture, and donor site pain [20–24]. In addition, the availability

Table 3
Clinical results

| | Preoperative back pain VAS | Postoperative back pain VAS |
|-----------|----------------------------|-----------------------------|
| AGF | 7.5±1.1 | 4.8±3.2 (p=NS) |
| Autograft | 7.7±1.7 | 4.77±3.0 (p=NS) |

AGF=Autologous Growth Factors; VAS=visual analog score.

Table 4
Functional outcome results

| | Oswestry | | SF-36 PCS | | SF-36 MCS | |
|-----------|-----------|-----------|-----------|-----------|-----------|-----------|
| | Pre | Post | Pre | Post | Pre | Post |
| AGF | 59.5±13.1 | 47.0±19.8 | 27.7±5.9 | 34.1±11.1 | 36.9±7.9 | 38.4±12.2 |
| Autograft | 60.0±18.8 | 36.7±24.7 | 29.0±6.5 | 38.1±11.6 | 32.9±10.2 | 39.7±12.8 |

AGF=Autologous Growth Factors; MCS=mental composite score; PCS=physical composite score; SF-36=36-Item Short Form Health Survey.

of graft is limited, and quality may be affected by systemic disorders such as osteoporosis. The incidence of donor site pain is reported to range from 2.5% to 49% depending on factors including diagnosis required for bone harvesting and the individual reporting the pain response (surgeon or patient).

The variable incidence of donor site pain and lack of consistent quality of autogenous bone has led to the development of alternatives to graft harvesting, including the use of adjunctive graft extenders (eg, allograft and demineralized bone matrices) and graft substitutes such as the potent osteoinductive bone morphogenic proteins. The issue of cost surrounding the use of bone morphogenic proteins has stimulated continued research on bone graft alternatives that may be more economically acceptable while still maintaining a comparable fusion rate to autograft. The current study specifically examined whether AGF combined with allograft could be a reasonable alternative to autograft harvested from the anterior iliac crest in interbody fusion. The graft composite studied and compared with autograft consisted of an osteoconductive carrier (allograft) with availability of bone marrow from perforations in the vertebral body end plates allowing for osteogenetic and osteoinductive requirements for an ideal graft. The application of platelet concentrates thus served as an osteopromotive agent for the graft composite and allowed for avoiding any harvest of anterior iliac crest and potential morbidity.

Our results suggest that AGF combined with allograft is comparable to autograft in lumbar interbody fusion at one or two levels with additional posterior fixation. The radiographic results suggest equivalency in terms of “early” healing evidenced by the computed tomographic analysis at 6 months postsurgery and at longer-term follow-up at 12 and 24 months. In addition, similar clinical outcomes were obtained for back pain relief, which was the primary surgical indication in our patients for this study. A specific questionnaire for iliac crest pain was not included in this study. Other studies evaluating the role of AGF and platelet concentrates have been reported and reveal variable effects of this technology. There are several preclinical studies depicting the effects of platelets on osteoblast function and proliferation [7,25,26], stimulation of recruitment of cells [27], and incorporation of cells into hydroxyapatite chambers [28]. Posterolateral lumbar arthrodesis rates comparable to autograft have been shown in sheep with the use of AGF combined with a resorbable osteoconductive carrier with additional bone marrow aspiration [29].

Most clinical studies have focused on the role of platelet concentrates in maxillofacial reconstructive surgery, but recently effects on spinal fusion have been reported. Lowery et al. reported on 19 patients in a retrospective review of AGF combined with allograft and/or autograft as an extender in posterior and anterior lumbar fusion [17]. There was no uniform randomization protocol or specific indication for the surgeries, and follow-up was limited to 1 year (13 months average follow-up). The authors reported 100% arthrodesis by radiographic analysis. Hee et al. evaluated the effect of AGF combined with autograft in transforaminal lumbar interbody fusion in 23 patients compared with an historical control of 111 patients with autograft only [15]. Four-, 6-, and 24-month radiographic evaluation was performed, with more rapid incorporation of fusion at 4 and 6 months in AGF patients (70% vs. 36% and 96% vs. 64%, respectively). At 24-month evaluation, no significant difference in fusion rate was detected (96% vs. 94%). The authors concluded that AGF could promote graft incorporation, stimulate faster union, and serve as an extender to autograft.

More recently, a retrospective analysis by Weiner and Walker reported on detrimental effects of AGF on autograft incorporation [14]. Patients underwent posterolateral non-instrumented arthrodesis with autograft alone (n=27) and autograft supplemented with AGF (n=32). Radiographic analysis at 12 and 24 months showed 62% intertransverse process fusion rate in the AGF group and 91% in the autograft group. The authors concluded that there must be an inhibitory effect of AGF on bone incorporation, and they postulated, although without scientific evidence, that this must be related to an unfavorable effect on the production or function of bone morphogenic protein. Based on computed tomographic analysis at 6 months after surgery, our study rejected any “delayed healing” effects of AGF. This then raises the question of whether the studies differ by preparation and handling of the platelet concentrate or if the osteopromotive effects of AGF are related to the site of bone graft incorporation (interbody vs. posterolateral lumbar spine) or the presence of mechanical stabilization.

Limitations to the current study are several. Platelet concentration was not determined and may not have been uniform among all patients, although the technique was similar for all patients, including the timing of blood sequestration immediately after induction of general anesthesia. Platelet handling can also affect degranulation and release of growth factors prematurely, and care was taken throughout

the study to prepare the concentrate as gently as possible before application into a graft composite. We did use stringent guidelines for interpretation of radiographic fusion and may have underestimated actual arthrodesis rates. Similar analysis was performed for both the autograft and AGF groups.

An interbody fusion model was used for this study, and a criticism is that a high fusion rate may occur with the use of allograft only. This is a reasonable criticism of the study; however, the literature regarding the use of allograft only in lumbar interbody fusion is variable, and published fusion results range from 25% to 93–100% in other studies [30–35].

An important point to clarify in the current study is that posterior fixation with autogenous iliac crest graft placed into the intertransverse area was used and therefore may be considered as a variable in affecting the incidence of anterior fusion. However, posterior autogenous graft has been reported to remodel and resorb over time in circumferential lumbar fusion with fixation and reasonably does not appear to affect eventual arthrodesis rates [36].


The sample size of the population studied was small. However, the focus of this report is on the effect of bone graft manipulation on fusion incorporation, and it is unlikely that a significant clinical outcome difference would be detected without enrolling a very large cohort of patients. The radiographic results are reasonably extrapolated from the results.

The conclusions from this study are several-fold: AGF combined with an allograft carrier is equivalent in radiographic and clinical outcomes to autograft in one- or two-level lumbar interbody fusion with supplemental posterior fixation; and no inhibitory effect of AGF was noted on graft incorporation. AGF combined with an appropriate carrier is a reasonable alternative to autograft and expensive bone induction technologies. Further research is still required to examine the optimum carriers, preparation and formulation, and platelet concentrations for this technology.

References

- [1] Kaplan K, Borekman C, Chernoff A, et al. Platelet alpha-granule proteins: studies on release and subcellular localization. *Blood* 1979; 53:604–18.
- [2] Knighton D, Hunt T, Thankral K, Goodson W. Role of platelets and fibrin in the healing sequence: an in vivo study of angiogenesis and collagen synthesis. *Ann Surg* 1982;196:379–88.
- [3] Lind M, Deleuran B, Thestrup-Pedersen K, et al. Chemotaxis of human osteoblasts. effects of osteotropic growth factors. *APMIS* 1995; 103:140–6.
- [4] Ferrara N, Houck K, Jakeman L, Leung D. Molecular and biological properties of the vascular endothelial growth factor family of proteins. *Endocr Rev* 1992;13:18–32.
- [5] Ross R, Raines E, Bowen-Poe D. The biology of platelet-derived growth factor. *Cell* 1986;46:155–69.
- [6] Kiritsy C, Lynch A, Lynch S. Role of growth factors in cutaneous wound healing: a review. *Crit Rev Oral Bio Med* 1993;4:729–60.
- [7] Slater M, Patava J, Kingham K, Mason R. Involvement of platelets in stimulating osteogenic activity. *J Ortho Res* 1995;13:655–63.
- [8] Marx R, Carlson E, Eichstaedt R, Schimmele S, Strauss J, Georgeff K. Platelet-rich plasma: growth factor enhancement for bone grafts. *Oral Surg Oral Med Oral Pathol Oral Radiol Endod* 1998;85:638–46.
- [9] Hannon T, Polston G, Pekarske W, et al. Determination of platelet yields from platelet rich plasma for five autotransfusion machines. *Anesth & Analg* 1996;88:104–9.
- [10] Eppley B, Woodell J, Higgins J. Platelet quantification and growth factor analysis from platelet-rich plasma (PRP): implications in wound healing. *Plastic Reconstruct Surgery* 2004;114:1502–8.
- [11] Zimmermann R, Jakubietz R, Jakubietz M, et al. Different preparation methods to obtain platelet components as a source of growth factors for local application. *Transfusion* 2001;41:1217–24.
- [12] Kevy S, Jacobson M. Comparison of methods for point of care preparation of autologous platelet gel. *J Extra Corp Technol* 2004;36: 28–35.
- [13] Walsh W, Loeffler A, Nicklin S, et al. Spinal fusion using an autologous growth factor gel and a porous resorbable ceramic. *Eur Spine J* 2004;13:359–66.
- [14] Weiner B, Walker M. Efficacy of autologous growth factors in lumbar intertransverse fusions. *Spine* 2003;28:1968–70.
- [15] Hee H, Madj M, Holt R, Myers L. Do autologous growth factors enhance transforaminal lumbar interbody fusion? *Eur Spine J* 2003; 12:400–7.
- [16] Bose B, Balzarini M. Bone graft gel: autologous growth factors used with autograft bone for lumbar spine fusions. *Adv Ther* 2002;19: 170–5.
- [17] Lowery G, Kulkarni S, Pennisi A. Use of autologous growth factors in lumbar spinal fusion. *Bone* 1999;25s:47–50.
- [18] Ware J, Sherbourne C. The MOS 36 Item Short Form Health Survey (SF36). I. Conceptual framework and item selection. *Medical Care* 1992;30:473–83.
- [19] Fairbank J, Pynsent B. The Oswestry disability index. *Spine* 2000;25: 2940–52.
- [20] Younger E, Chapman M. Morbidity at bone graft donor sites. *J Ortho Trauma* 1989;3:192–5.
- [21] Summers B, Eisenstein S. Donor site pain from the ilium: a complication of lumbar spine fusion. *J Bone Joint Surg* 1989;71B: 677–80.
- [22] Fernyhough J, Schimandle J, Weigel M, Edwards C, Levine A. Chronic donor site pain complicating bone graft harvesting from the posterior iliac crest for spinal fusion. *Spine* 1992;17:1474–80.
- [23] Goulet J, Senunas L, DeSilva G, Greenfield M. Autogenous iliac crest bone graft: complications and functional assessment. *Clin Ortho Rel Res* 1997;339:76–81.
- [24] Heary R, Schlenk R, Sacchieri T, Barone D, Brotea C. Persistent iliac crest donor site pain: independent outcomes assessment. *Neurosurg* 2002;50:510–6.
- [25] Schecroun N, Delloye C. In vitro growth and osteoblastic differentiation of human bone marrow stromal cells supported by autologous plasma. *Bone* 2004;35:517–24.
- [26] Arpornmaeklong P, Kochel M, Depprich R, Kubler N, Wurzler K. Influence of platelet-rich plasma on osteogenic differentiation of rat bone marrow stromal cells: an in vitro study. *Int J Oral Maxillofac Surg* 2004;33:60–70.
- [27] Oprea W, Karp J, Hosseini M, Davies J. Effect of platelet releasate on bone cell migration and recruitment in vitro. *J Craniofac Surg* 2003;14:292.
- [28] Seibrecht M, De Rooij P, Arm D, Aspenberg P. Platelet concentrate increases bone ingrowth into porous hydroxyapatite. *Orthopaedics* 2002;25:169–72.
- [29] Walsh W, Loeffler A, Nicklin S, et al. Spinal fusion using an autologous growth factor gel and a porous resorbable ceramic. *Eur Spine J* 2004;13:359–66.
- [30] Sarwat A, O'Brien J, Renton P, Sutcliffe J. The use of allograft (and avoidance of autograft) in anterior lumbar interbody fusion: a critical analysis. *Eur Spine J* 2001;10:237.

- [31] Liljenqvist U, O'Brien J, Renton P. Simultaneous combined anterior and posterior lumbar fusion with femoral cortical allograft. *Eur Spine J* 1998;7:125–31.
- [32] Brantigan J. Pseudarthrosis rate after allograft posterior lumbar interbody fusion with pedicle screw and plate fixation. *Spine* 1994;19:1271–9.
- [33] Kumar A, Kozak J, Doherty B, Dickson J. Interspace distraction and graft subsidence after anterior lumbar fusion with femoral strut allograft. *Spine* 1993;18:2393.
- [34] Butterman G, Glazer P, Bradford D. The use of allografts in the spine. *Clin Ortho Rel Res* 1996;324:75–85.
- [35] Janssen M, Lam C, Beckham R. Outcomes of allogeneic cages in anterior and posterior lumbar interbody fusion. *Eur Spine J* 2001;10:s158–68.
- [36] Gill K, O'Brien J. Observations of resorption of the posterior lateral bone graft in combined anterior and posterior lumbar fusion. *Spine* 1993;18:1885–9.



Four Hundred Forty Years Ago in Spine

In 1665, Robert Hooke described his construction of a compound microscope and his observations in the first work that dealt only with microscopic findings and the first English-language treatment of the

topic [1]. It contains copperplate engravings of drawings by Hooke and probably also by Sir Christopher Wren. The work introduced the word “cell” in describing microscopic appearance of tissue. Hooke’s work preceded van Leeuwenhoek’s microscopic descriptions of spermatozoa, red blood cells and protozoa [2].

References

- [1] Hooke R. *Micrographia, or some physiological descriptions of minute bodies made by magnifying glasses; with observations and inquiries thereupon*. London: J Martyn & J Allestry, 1665.
- [2] Leeuwenhoek A van. *Ontledingen en ontdekkingen*. 6 vol. Leiden: Delft, 1693–718.